

# EDITORIAL

Adv Clin Exp Med 2015, 24, 1, 5–14  
DOI: 10.17219/acem/31880

© Copyright by Wrocław Medical University  
ISSN 1899–5276

MACIEJ CHWAŁA<sup>1, D</sup>, WOJCIECH SZCZEKLIK<sup>2, E–F</sup>, MICHAŁ SZCZEKLIK<sup>3, E</sup>,  
TOMASZ ALEKSIEJEW-KLESZCZYŃSKI<sup>4, E</sup>, MARIA JAGIELSKA-CHWAŁA<sup>5, E</sup>

## Varicose Veins of Lower Extremities, Hemodynamics and Treatment Methods

<sup>1</sup> Clinical Department of Vascular Surgery, University Hospital, Kraków, Poland

<sup>2</sup> Allergy and Immunology Clinic, University Hospital, Jagiellonian University Medical College, Kraków, Poland

<sup>3</sup> Department of Cardiothoracic Surgery, London Chest Hospital, London, United Kingdom

<sup>4</sup> Vascular Surgery Medical Centre, Kraków, Poland

<sup>5</sup> Vascular Centre, St. John Grande Hospital, Kraków, Poland

A – research concept and design; B – collection and/or assembly of data; C – data analysis and interpretation;  
D – writing the article; E – critical revision of the article; F – final approval of article; G – other

### Abstract

Chronic venous insufficiency is one of the most common disorders of the vascular system, affecting approximately 50% of adults. If left untreated it can lead to a number of complications, including venous ulceration and venous thrombosis. This review paper outlines the epidemiology and etiopathogenesis of the disease with regard to hemodynamics and microcirculation disturbances. It describes the medical treatment as well as the traditional surgical approach to varicose veins (with several modifications of this technique), and its limitations and contraindications. Furthermore, it discusses a number of new, minimally invasive treatment methods, namely thermal in form (radiofrequency ablation, endovenous laser ablation, steam ablation) and nonthermal (sclerotherapy, echosclerotherapy, Clarivein, Sapheon). For each method, there is a brief historical overview, a description of its mechanism of action, and its indications and limitations. The results of comparative studies on individual treatment methods as well as meta-analyses on this topic are briefly discussed. This paper highlights the progressive trend towards minimally invasive methods and attempts to predict the further development (*Adv Clin Exp Med* 2015, 24, 1, 5–14).

**Key words:** varicose veins, laser ablation, radiofrequency ablation, sclerotherapy, surgical management of varicose veins.

For many years, chronic venous disease has been considered a merely cosmetic or psychological problem. However, research on this disorder points to its serious consequences such as absence from work, discomfort, pain, and an objectively measured decline in quality of life [1].

The various stages of the condition are classified by the CEAP classification. In stage C1, the disease manifests itself as spider veins and reticular veins [2]. Stage C2 includes uncomplicated varicose veins. The more advanced stages of the disease are referred to as chronic venous insufficiency. In stage C3 oedema, without skin changes, is present. Advanced skin lesions such as lipodermatosclerosis or trophic changes (C4) as well as healed (C5) and active ulcerations (C6) are complications seen in more advanced stages. Consequently, it can

lead to the loss of the affected limb, and can even be life threatening [3].

The real social significance of chronic venous insufficiency lies in its prevalence and in the cost of the treatment spread out over many years. Epidemiological studies conducted in Poland, which included more than 40,000 patients, indicate that the disease affects 61% of women and 38% of men in the adult population [4]. Some epidemiological studies indicate less variation in the incidence of the disease between the sexes, whereas others suggest an inverse proportion [5].

The most severe stage, active venous ulceration, affects less than 1% of the population (in Poland this is observed in up to 0.5% of adults), but is seen in 3% of patients over age 65 [6]. The incidence of varicose veins increases with age, as

it is a chronic degenerative disease. As the population's life expectancy increases we can expect to see an increase in the incidence of the disease. One of the consequences will be an increase in the cost of treatment of the disease and its complications.

## The Mechanism of Venous Blood Return

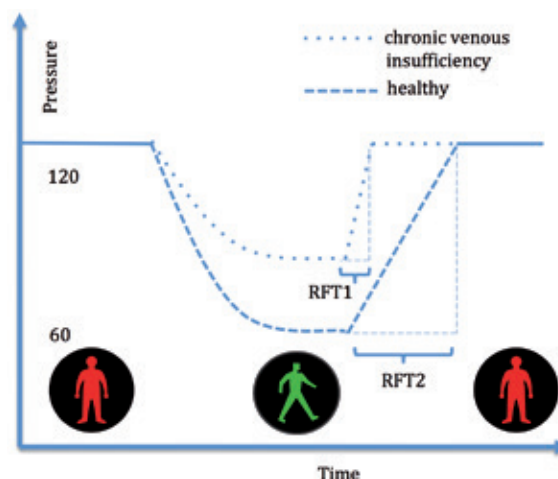
The return of venous blood from the lower extremities is dependent on a number of factors. Human upright posture necessitates mechanisms that assist in emptying the venous vessels. Deep veins are located between the large muscle groups inside the myofascial compartments. In normal conditions, during muscle contractions, pressure generated within the fascial compartment is directly transferred to the veins, directing venous blood flow towards the heart through competent venous valves. During increased effort, the pressure can reach up to 5 bars [7]. Due to this mechanism, over 90% of venous blood volume leaves the lower limb via the deep vessels. Located outside of the fascia, superficial vessels are connected to the deep venous system *via* the sapheno-femoral and sapheno-popliteal junction and perforator veins. Their task is to drain venous blood from the skin and subcutaneous tissue. The direction of the blood flow from the superficial to the deep venous system is maintained by the existing pressure differences and the Bernoulli effect, in which a drop in the pressure resulting from accelerated blood flow in the deep veins causes sucking of the blood from the superficial veins.

If a healthy person of average height stands still for a few minutes, hydrostatic pressure in the venous system of the foot reaches about 120 cm of the water column. Achieving such pressure values is accompanied by discomfort and causes involuntary muscle contractions (activation of the muscle pump). Both involuntary and voluntary muscle pump activation results in a pressure drop of approximately 60%. Thus, a properly functioning muscle pump prevents an increase of pressure in the standing position. As a result, the pressure at the venous end of the capillary is at a similar level to a supine position.

On the contrary, in venous insufficiency the pressure after marching or standing on tiptoes is not adequately reduced and/or its high value is restored after only a short period of stillness (Fig. 1).

## Microcirculation

The delicate structure of microcirculation does not tolerate high hydrostatic pressure. The protective mechanisms are located in the “high pressure”,



**Fig. 1.** The influence of the muscle pump on the pressures changes in a superficial venous system in healthy adults and patients with chronic venous insufficiency. In healthy subjects the drop in pressure after pump activation is greater and the time required to refill the vascular bed (RF-refilling time) is longer.

i.e. arterial side, where precapillary sphincters and arterioles can be found. But microcirculation is not in any way protected against blood pressure fluctuations from the venous side. Therefore it requires precise mechanisms for ‘pumping out’ the venous blood in order to avoid microcirculation “overflow”. Otherwise a disturbed pressure profile from the venous side is directly transferred into microcirculation leading to a sequence of events, such as endothelial cell activation, extravasation of macromolecules and red blood cells, immune system activation, and leukocyte diapedesis. The consequent chronic inflammation leads to tissue damage, including tissue necrosis and ulceration [8].

## Varicose Veins

Primary varicose veins are one of the manifestations of chronic venous disease. Degeneration of trunks and valves leads to an abnormal flow of venous blood from the deep venous system to the superficial system and a flow downwards in the superficial system itself. Thus, blood flow generated in the deep venous system cephalad is undermined by the opposite direction of the flow in superficial veins, where the blood flows down as if *via* ‘gutters’. Consequently, after being drained by muscle contractions, the venous system is quickly refilled up to a maximum hydrostatic pressure with blood flowing through insufficient superficial vessels. The greater the diameter of the insufficient trunks, the faster the maximum pressure is reached. Moreover, the deep vein system needs to ‘pump in’ the

same blood. This volume overload, if maintained for many years, leads to secondary irreversible changes in the deep venous system.

## Medical Treatment

Therapeutic management of chronic venous disease can be based on conservative (medical) or invasive methods.

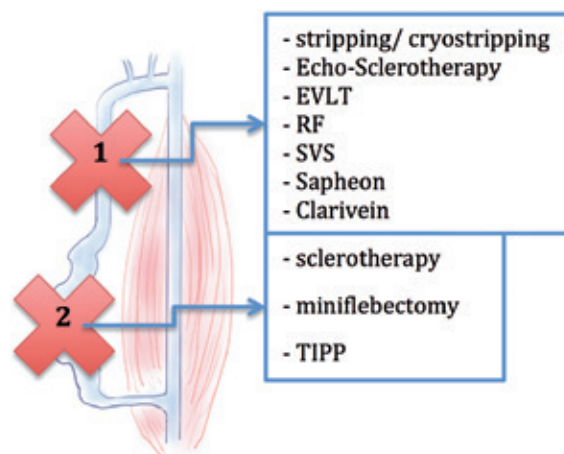
Medical treatment of chronic venous disease involves the use of the following:

- lifestyle changes (weight loss, exercise, periodic limb elevation, rehabilitation of the ankle joint, avoidance of a standing position and a sitting position with lowered limbs)
- compression therapy – using compression bandaging or graduated compression products, when properly selected, effectively reduces edema and pain. However, their tolerance may be problematic, especially in the summer.
- pharmacotherapy – phlebotropic drugs, acting primarily by modifying the venous tone, reduce the severity of inflammation and vascular permeability of capillary vessels, which in turn leads to a decrease in pain, symptoms and edema.

## Invasive Treatment

The essence of invasive treatment of venous insufficiency in more advanced stages (CEAP C2 and above) lies in breaking the circuit of venous vessels in which reflux is present. Additionally, a Doppler examination of the deep venous system to confirm vessel patency is necessary prior to invasive treatment. Currently, there are no known effective methods for repairing insufficient valves except for therapies that are still in the experimental phase. However, a number of new methods are worth mentioning, including attempts to transfer a healthy autologous valve mounted within a self-expanding stent to the insufficient vessel [9]. Recognizing varicose veins as closed circuits justifies either the selective ablation of an inefficient trunk or solely of a varicose vein as a final form of treatment:

- Ablation of the trunk of an insufficient great/small saphenous vein often leads to the complete regression of varicose veins due to the lack of inflow 'from the top'.
- Alternatively, closing varicose veins may result in the disappearance of reflux in the great saphenous vein (because the blood has no space to drain).
- More severe stages require the removal of both of the above components along with re-entry



**Fig. 2.** Surgical methods used in varicose vein treatment with respect to inefficient major vessel trunks (1) and varicose veins (2). EVLT – endovenous laser treatment, RF – radiofrequency, SVS – steam vein sclerosis, TIPP – transilluminated powered phlebectomy.

perforators. Treatment can therefore be divided into correcting reflux in the venous trunks and removing the varicose veins (Fig. 2).

## Surgical Methods

Surgical (traditional) treatment is the oldest method for dealing with varicose veins. The operating technique was developed in 1905 by William Wayne Babcock and is still used with some modifications.

In the most common case of great saphenous vein (GSV) insufficiency, the procedure starts with a skin incision in the sapheno-femoral junction region. All the tributaries of the greater saphenous vein near its ostium must be located and dissected. Eventually, the saphenous vein itself should be dissected, its end flush ligated with the femoral vein, leaving the shortest possible vein stump – this part of the procedure is called a crossectomy. Subsequently, another skin incision should be made along the course of the saphenous vein. Currently, this is most commonly done at or just below the knee. A stripper – a metal probe with a bulbous tip – is placed inside the vein, and the tip of the stripper emerges at the free end of the vein in the inguinal region. After the fixing, the saphenous vein is removed. Nowadays, in most cases only the femoral section of GSV is removed, leaving the vein in the lower leg. This approach is associated with lower risk of post-procedure neurological complications, and the remaining fragment of the vein may serve as a conduit for future vascular

or cardiac surgery. To reduce the invasiveness of the procedure the technique of invagination stripping can be performed – the free end of the vein fixed on the stripper is inserted ‘inside’ the vessel, and the vein is removed in a similar way to a finger being pulled out of a rubber glove, or a stocking stripped ‘inside out’.

Cryostripping is the alternative. In this method, after performing a crossectomy, the probe is inserted into the saphenous vein peripherally up to the level of the knee. Then, the ending of the probe supplied with liquid nitrogen is cooled off, causing the saphenous vein to freeze up to the tip. The distal section of the removed vein breaks, while the proximal part is removed together with the probe, similarly to stripping by invagination.

Low temperatures decrease the bleeding from the tributaries along the course of the GSV, thereby reducing the risk of hematomas. Importantly, another incision in the limb can be avoided, apart from access to the saphenofemoral junction [10].

In conventional surgery, as a complement to the stripping technique, varicose veins are most often removed simultaneously. A small incision is made along the course of the varicose vein every few centimeters in order to extract them above the skin using a special hook; the vessel is divided, and both formed ends of the vein are ripped off (so-called hook phlebectomy, miniflebectomy). Insufficient perforators are treated in an analogous manner. If incisions are suitably small, wounds can be left without skin sutures, resulting in a better cosmetic effect.

A modification of this method is transillumination powered phlebectomy (TIPP), which involves mechanically removing the varicose veins. Inserted by puncturing into subcutaneous tissue, the transilluminator (strong light source) helps locate varicose veins, which are then broken into pieces and sucked out by a special tip [11]. Varices are removed with fewer incisions, and may be removed from areas in close proximity to venous ulcers without the risk of infecting wounds, as the tip of the device can be inserted under the skin at a reasonable distance from the wound. The disadvantages include the price of the equipment, skin recesses formed as a result of adipose tissue suction, and skin discoloration.

Importantly, conventional surgery has no limitations in terms of size, location and course of the vessels to be operated on. In Poland, it remains the only form of treatment refunded by the National Health Fund.

The main complications of surgical treatment are postoperative pain and hematomas, especially along the course of a saphenous vein removed *via* stripping, resulting from disruption of the

tributaries. Wound infection and sensory disturbances due to the removal of skin nerves have also been observed.

Postoperative scarring undermines the cosmetic result of the treatment. Rare complications include damage to the arterial system in the inguinal region, damage to deep veins, and deep vein thrombosis [12].

The major problem associated with surgical treatment is the risk of relapse. The reported rate of relapse at 5 years varies between 50 and 65% [13]. According to the international consensus on post-surgical recurrent varicose veins (REVAS) [14] approved in Paris in 1998, there are several types of recurrent varicose veins. Despite proper surgical treatment, veins that were “healthy” at the time of the initial surgery may degenerate over time. The progression of the disease is responsible for between 20% and 25% of the relapses described in the literature [15].

Varicose veins that appear up to a month after the surgery most frequently result from an inadequate technique or tactic (e.g. leaving one of the insufficient trunks in place, an overly long GSV stump with tributaries, removal of the incorrect venous trunk). Another term used to describe this pathology is residual varicose veins. Only those varicose veins that were formed in the area affected by the surgical procedure at least one month after the surgery can be regarded as real recurrent varicose veins.

Initially, it was thought that as with residual varicose veins, the majority of recurrences could be regarded as a consequence of poor surgical technique. However, with the prevalence of ultrasonography it was found that a significant percentage of recurrences occur despite adequate surgical treatment. The process responsible for the formation of recurrent varicose veins was defined as neovascularization. Over a period of several years, new blood vessels form in patients postoperatively and these eventually take over the function of the removed insufficient trunk vein – most commonly the great saphenous vein. Studies using ultrasound indicated the presence of such vessels in 14% of patients one year after surgery [16]. Neovascularization appears to be responsible for between 8 and 60% of secondary varicose veins [17].

The vessels formed during neovascularization have an immature and incomplete wall structure (neither media nor adventitia present), and do not have valves. The wall is thin, and the course is sinuous (hence the common term used to describe changes visible in the ultrasound in the groin is cavernous angioma – cavernoma). From a histological point of view, the vessels have neither elastic fibers in their walls nor nerve fibers, and are



surrounded by scar tissue [18]. These are formed by the budding of the vascular endothelium at the edges of veins cut during surgery, in a process that probably involves released growth factors, metalloproteinases, hypoxia, a venous pressure gradient, and local inflammation. To some extent, the neovascularization process may be regarded as an aberration of normal neoangiogenesis in granulation tissue formed in the surgical wound [19]. Venous lesions formed as a consequence of neovascularization not only decrease the patient's satisfaction, but are also regarded as posing considerable technical difficulties in the case of re-operation. They increase the perioperative risk, and the effect of the treatment is usually much worse than the primary operation [20].

## Non-Surgical, Intravascular Methods

Some techniques are more likely to induce neovascularization than others. In the intravascular methods there is no disruption in the vascular continuity, therefore no endothelial exposure, scarring, granulation tissue, or hematoma formation. The results confirm a reduced risk of neovascularization following non-surgical treatments. The percentage of neovascularization after endovascular treatment is between 1% and 1.5%. One prospective study showed that no neovascularization was observed five years after treatment for great saphenous vein reflux with radiofrequency [21].

Intravascular techniques damage the venous wall, resulting in fibrosis and clot formation. A damaging agent – thermal, electrical, chemical, mechanical, or a combination of these – is usually applied through a small puncture without the need to prepare a vein. However, in order to locate a vein, ultrasound navigation becomes necessary. Positioning in relation to the junction with deep veins is also based on ultrasonography techniques. Thus current revival in intravascular techniques is in part a consequence of technological advances and a drop in the price of ultrasound devices.

Besides the absence of scarring and the avoidance of neovascularization, another potential benefit of alternative treatments is the low risk of infection. This makes it possible to use local anesthesia and to operate on patients with active ulcerations. It also facilitates a two-stage approach (first, either the great or small saphenous vein trunks are closed and then, after a time interval, the varicose veins may be dealt with, only if spontaneous involution did not occur first). Faster convalescence and shorter absence from work following intravascular procedures are also important factors.

The non-surgical methods can be classified into thermal techniques, which require the use of anesthesia and intumescence, and nonthermal techniques. The first group consists of endovenous laser ablation (EVLT), radiofrequency ablation (RF), and steam vein sclerosis (SVS). The second group comprises sclerotherapy, echosclerotherapy, the Saphenon method, and the ClariVein method.

A number of pioneering intravascular ablation procedures were performed in Krakow, Poland in the 1960s by a team headed by Prof. Politowski. These procedures were performed using a standard electrocoagulation kit with the appropriate tip inserted into the great saphenous vein after its dissection [22]. Unfortunately, the technique was abandoned due to postsurgical complications and, from today's perspective, no appropriate imaging facilities.

Intravascular procedures began to develop on a larger scale after the year 2000. One of the first reports on this subject describes a great saphenous vein closure technique using radiofrequency (RF) waves [23].

The method is based on the phenomenon of heat generation in the tissues around the conductor in which a current alternating in radio frequency (300 KHz to 1 MHz) flows. A current at such a high frequency does not trigger potentials in excitable cells. As a consequence, the RF procedure is less painful and does not cause secondary muscle contractions. The temperature of 85–120 degrees generated around the probe destroys the endothelium with secondary vasoconstriction, the coagulation of blood in the vessel lumen, and the denaturation of proteins in the vein wall, leading in turn to its permanent occlusion. Over time, the vein undergoes fibrosis and an ultrasound reveals an image of thin bands of connective tissue (fibrous cord).

The procedure involves puncturing the vein to be treated under ultrasound guidance, and inserting a vascular sheath (Seldinger's method) into the vein. The most common vein to be punctured is the great saphenous vein near the knee (where it is easy to locate, has a relatively simple course, and is not accompanied by a saphenous nerve). Subsequently, a catheter is inserted into the vessel with an RF tip, and the catheter tip under ultrasound control is positioned approximately 2 cm distally from the saphenofemoral junction.

Tumescent anesthesia is also performed under ultrasound control. In this method, a large volume of liquid is injected into the tissues surrounding the treated vein along its course. This creates a secure barrier separating the vein from the surrounding tissue (in particular from the adjacent deep veins, nerves and away from the skin),

and increases the adhesion of the venous wall to the catheter. Since the fluid contains an anesthetic substance, an analgesic effect is achieved. In order to drain superficial veins of blood, the limb being operated on is raised up. Subsequently, vein ablation is performed along its entire length as the catheter is gradually withdrawn.

The latest devices allow simultaneous coagulation of a vein segment up to 7 cm in length, while the device monitors the temperature of the catheter tip (about 120 degrees Celsius), and the time of energy application (sound pulse emitted every 20 s). Next, the catheter is advanced a further 7 cm. This technique allows for a very precise and reproducible dosage of energy (Venefit™ procedure using Covidien ClosureFast™ catheters). Other devices require continuous movement of the tip (e.g. a bipolar Olympus Celon probe, which operates at a much lower temperature of 85 degrees). Currently, there is no data in the literature comparing both methods. The effectiveness achieved by the RF procedure reaches 93% of closed veins within 3 years [24].

When the RF method was compared with the EVLT (980 nm laser ablation) improvement according to the Venous Clinical Severity Scores (VCSS) and the CVIQ2 questionnaire evaluating the quality of life was faster after the former. Less severe pain and fewer complications were also noted in patients treated with RF [25].

Possible complications following RF treatment include bleeding, infections, thermal damage to the nerves (in particular the saphenous nerve and the sural nerve), deep vein thrombosis, and skin discoloration. Because of the specific construction of the RF catheter, introducing it through the tortuous sections of the veins and post-thrombotic vessels can be difficult.

Another method for treating varicose veins is based on the use of laser light – this is called endovenous laser ablation (EVL) [26]. From a technical point of view, it is similar to RF treatment. The advantage of the laser approach is the presence of a so-called pilot, i.e. a red spot of light visible through the skin at the end of the fiber, allowing for the positioning of the tip, in addition to the ultrasound. In contrast to RF, it is not possible to monitor the temperature or the energy dose delivered in laser surgery. It is determined empirically on the basis of the laser power and the speed at which the fiber is pulled. The values recommended for the 810 nm laser oscillate between 50 to 80 J/cm [27] (e.g. when the power is set at 14 watts, the tip of the optical fiber should move 1 cm in 5 s). The laser light causes a local increase in temperature of up to 800 degrees Celsius at the top of the fiber. As a result, in addition to the fact that

the vein wall is directly exposed to laser light, there is also a significant increase in blood temperature around the optical fiber and the blood boils (steam bubbles visible on ultrasound examination). The high temperature transferred by blood damages the vein wall evenly within the short segment. As a result of both processes the endothelium becomes completely destroyed, the collagen in the vessel wall is denaturated, and its lumen coagulated [28]. The laser wavelengths of 810, 940 and 980 nm, that were introduced initially, are absorbed by deoxyhemoglobin, which results mostly in heating of the blood. Direct action of these wavelengths on the vessel wall is weaker. The light of the recently introduced (Biolitec™) 1470 nm lasers is absorbed by the water contained in the tissue and it acts more selectively on the venous wall. Thus, lower energy doses can be used to cause vein closure, which results in decreased levels of pain in the postoperative period and a lower risk of perforating the vessel wall, reducing postoperative haematomas.

Besides the introduction of various wavelengths, the evolution of lasers techniques involves modifications to optical fibers. Apart from classical optical fibers with a diameter of 200–600 microns, which beam light “forward”, companies have also introduced so-called radial optical fibers equipped with a special tip capable of changing the direction of the laser beam so that they also illuminate “sideways”, forming a ring of light 360 degrees around the fiber. As a result, the direct impact on the vein wall is increased, which makes it possible to close a vessel with a larger diameter. It also reduces the risk of vein wall perforation by the beam focused in front of the fiber.

EVL complications and limitations are similar to those present in radio frequency ablation. In the case of EVLT, there is a greater risk of the vein being perforated and hence an increased risk of hematoma. Furthermore, the pain experienced is slightly more severe, which is most likely due to the much higher temperatures achieved during laser treatment [29]. At the same time, the method is more effective [30].

The most recent thermal method of treatment is steam therapy (SVS Steam Vein Sclerosis). On the basis of indirect action of EVLT due to the formation of steam bubbles transmitting energy to the venous wall, a device has been designed to generate steam pulses heated to a temperature of 120 degrees Celsius. The steam is delivered to the vein by a catheter. The procedure is analogous to RF and EVLT. By dissipating its energy, the steam immediately condenses while 1 g of steam during condensation transfers 2258 J. Therefore, assuming the need to deliver about 50 J of energy per

one centimeter of vein, steam generated from just 2 ml of water is sufficient to close a 30 cm long section of the great saphenous vein. Steam bubbles produced by the generator have fixed parameters – 76 microliters of water is used to produce a single pulse. Thanks to this, the amount of energy is strictly controlled. Steam impulses are generated every centimeter along the catheter route. The catheter is thin (1.2 mm diameter) and flexible; therefore, it can be used to close varicose veins and perforators. Due to these benefits, a complete operation can be performed by means of steam without the need for additional miniflebectomy or sclerotherapy, nor a second stage flebectomy. The method is promising, but there is insufficient data supporting its long-term effectiveness [31].

Nonthermal methods constitute another approach to varicose vein treatment. One of the advantages of these techniques is that no anesthesia is needed, which decreases the risk of the procedure. By omitting intumescence, additional numerous punctures and secondary hematomas can be avoided. As no high temperature is used, there is no risk of skin burns or damage to the nerves and muscles adjacent to the ablated veins. This contributes to reduced perioperative pain.

From a historical point of view, sclerotherapy offered the first alternative to classical surgery. This approach was based on observations of idiopathic varicose vein thrombosis, which showed that during the course of the disease, some patients experienced reduced symptoms due to fibrosis and secondary occlusion of varicose veins. This led to efforts to find a substance that would cause sterile inflammation in the vein. This approach, combined with compression therapy, leads to irreversible vein fibrosis. Various groups of chemicals were used to obliterate varicose veins, such as hyperosmotic agents (saline solution or glucose), irritants (chromed glycerol), and detergents. The latter group currently includes the most widely used substances, i.e. tetradecyl sulfate (STD) and Polidocanol (Aetoxysclerol). The sclerotherapy involves injecting sclerosant into the target vessels. Detergents cause damage of the vascular endothelium, which results in the exposure of the vessel's deeper layers. The vessel contracts immediately, followed by thrombus formation and sterile inflammation of the vascular wall. This method is now safer due to the introduction of detergents that do not have a strong cytotoxic effect (they remove endothelial cells by dissolving intercellular connections). Consequently, the risk of tissue necrosis following the accidental administration of the medicine outside the target area is minimal.

When large venous vessels are obliterated, painful lumps can form along closed veins,

usually approximately two weeks after the procedure. These consist of blood clots formed in the vessel and secondary breakdown products of red blood cells with the osmotic properties. In the above situation, the vessel is punctured, thereby draining its semi-liquid content (sclerothrombus). External pressure applied to obliterated areas immediately after treatment aims to minimize the above consequences. Sclerosant activity is restricted solely to the superficial veins due to its rapid deactivation by plasma proteins and immediate dilution of the drug by the large amount of blood flowing through the deep venous system. These two mechanisms prevent the vessels from causing deep vein thrombosis; however, for many years they have also been the main factors limiting the efficacy of the method (especially when larger venous trunks with a rapid blood flow were to be treated) [32]. Elevating the limb and using the so-called air-block technique, i.e. the administration of a small volume of air into the vessel in order to displace blood, helped solve this problem. The sclerosant injected afterwards is consequently undiluted and able to affect the wall more efficiently, encouraging a local effect.

However, sclerotherapy only really achieved its renaissance after the introduction of the foam method. Due to the chemical properties of detergents, they have the ability to form a foam when mixed with air or other gases. The foam distributes in the vessel, displaces the blood, and remains at the injection site. As a result, the potency of foam is several times higher than that of the drug in the liquid form. The ability to control the area in which the foam is active is also better, and penetration into the deep venous system is slower.

The next step in the development of sclerotherapy came with the implementation of ultrasound technology. Foam is an excellent ultrasound contrast agent, so its position in the vessel and the area of its operation can easily be controlled. Moreover, thanks to the support of ultrasound it was possible to access deeper vessels, invisible through the skin. This allowed for a comprehensive approach to treating varicose veins, regardless of the severity of the disease.

Sclerotherapy was previously used mostly in the treatment of spider veins, telangiectasia, and reticular veins. Discouragement concerning treatment of varicose veins resulted from common recurrence of the problem, mainly caused by leaving untreated saphenous vein trunks (great or small). Foam sclerotherapy with ultrasound guidance, also referred to as echosclerotherapy, enabled closing trunks as large as 10 mm in diameter. Its effectiveness is comparable to surgical methods and is slightly worse than thermal treatment. Other

advantages of sclerotherapy include its relatively low price and the fact that it can be administered in an outpatient setting. Sclerotherapy is also an excellent method for treating recurrent varicose veins – due to their sinuous course, wall structure, and the coexistence of scars that prevent the use of RF and lasers, as well as the increased risk of classical operations. The disadvantage of sclerotherapy is that there is a risk of long-lasting discoloration of the skin in the vicinity of the closed vessels. Because of the need to remove hematomas and the need to repeat the procedure due to the limited amount of the drug that can be administered safely, the treatment is a lengthy process and often takes several weeks. Potential complications of the treatment include venous thrombosis (activation of the coagulation system during sclerotherapy has been proven), allergic reactions, and tissue necrosis. The most serious complications occur with accidental intra-arterial administration, which may lead to necrosis of the limb, possibly necessitating secondary amputation of the limb. Specific complications of the foam method result from migrating gas bubbles. Most of the time they will end up in the pulmonary circulation, however in the presence of a patent foramen ovale (PFO), they can migrate to the systemic circulation. In such cases, they can cause damage to the central nervous system, resulting in temporary visual disturbances, headaches, and in very rare cases, a stroke. According to another theory, neurological complications occur due to post-procedural increased endothelin activity, which affects the cerebral vessels [33]. Because foam sclerotherapy is not FDA approved it is still treated as an off – label method in the USA, and alternative methods are being sought.

“ClariVein” method enhances the action of the chemical sclerosant through mechanical damage and irritation of the venous wall. The author of this method uses the analogy of a washing machine, which also mechanically increases the penetration of the detergent, and thus enhances its strength. Developed in 2005, the mechanochemical method of vein ablation involves the use of a catheter with a rotating tip. The procedure is similar to that for EVLT or RFA. A flexible catheter with a 2 cm long elastic wire at its end is inserted 2 cm below the saphenofemoral junction. Subsequently, elastic wire at the end of the catheter rotates with a frequency of 3500 rpm in a circular motion, damaging the endothelium and causing intense contraction of the vein. At the same time, a liquid sclerosant is applied from the catheter just below the rotating tip. The tip is pulled along the vein approximately 1–2 mm per second. The advantage of this procedure is the time – complete greater saphenous vein ablation takes approximately 14 min. This

method is used to treat lower leg sections of the venous trunks without the risk of adjacent nerve damage. It does not require an external generator, because the grip includes a battery-powered motor, controls the application of the sclerosant and is integrated with the catheter (ClariVein). The number of studies assessing this method is small. In one of them, the effectiveness was estimated at 97% of all great saphenous vein occlusions within 6 months [34].

In another method, “Sapheon”, an adhesive substance (a tissue glue derived from cyanoacrylic glue), is applied into the vein lumen in order to obliterate the vessel. Originally, similar compounds were used to obliterate the hemangiomas and varicose veins of the esophagus. The specific property of cyanoacrylic adhesives enables their rapid polymerization in the presence of water and their high affinity to tissue. When introduced into the vein, the adhesive causes closure of its lumen primarily mechanically. However, the essence of the method is the secondary aseptic inflammatory reaction caused by a foreign body that ultimately leads to fibrosis of the vein [35]. The adhesive substance is applied by a catheter and it takes about 1.6 mL of the adhesive to treat the great saphenous vein. An important feature of this method is the possibility of avoiding compression therapy after treatment since its effect is immediate. Observations indicate that the method is immediately 100% effective (48–72 h observation), and is 97% effective within a month. However, current studies have only covered a small number of patients, and the observation time was short.

## Conclusions

Due to its incidence, chronic venous insufficiency of the lower limbs poses a challenge to modern society. Although medical treatment helps to stop its progress, it is not curative. The invasive methods provide an improvement in quality of life, including improved aesthetics. They also help to prevent the onset of future serious consequences of the disease, including development of irreversible deep vein insufficiency and the progression to venous ulcerations [36]. Randomized studies confirm the improved cost effectiveness of surgical treatment in comparison with compression therapy [37].

It is not surprising that the number of stripping-based surgical procedures carried out has declined (155 000 in the U.S. in 1999, only 40 000 in 2007). This can be explained by the growing popularity of minimally invasive treatment, as the number of procedures has increased from 80,000 to



195,000 in just three years [38]. This is at least partially due to the availability of this type of treatment for physicians specializing in areas other than general or vascular surgery, such as dermatologists and angiologists. But a more important reason is the patients' comfort, faster recovery time, and better

aesthetic results. Most importantly, the modern minimally invasive methods, as shown in a large meta-analysis, are very effective with the 5-year efficacy rates ranging from 95% for EVLT, 80% for RF, and 74% for sclerotherapy, while traditional operation with stripping has 76% efficacy [39].

## References

- [1] **Kaplan RM, Criqui MH, Denenberg JO, Bergan J, Fronck A:** Quality of life in patients with chronic venous disease: San Diego population study. *J Vasc Surg* 2003, 37, 1047–1053.
- [2] **Eklöf B, Perrin M, Delis KT, Rutherford RB, Gloviczki P:** Updated terminology of chronic venous disorders: the VEIN-TERM transatlantic interdisciplinary consensus document. *J Vasc Surg* 2009, 49, 498–501.
- [3] **Korn P, Patel ST, Heller JA, Deitch JS, Krishnasastri KV:** Why insurers should reimburse for compression stockings in patients with chronic venous stasis. *J Vasc Surg* 2002, 35, 950–957.
- [4] **Jawień A, Grzela T, Ochwat A:** Prevalence of chronic venous insufficiency (CVI) in men and women of Poland. Multicenter cross-sectional study of 40095 patients. *Phlebology* 2003, 18, 110–122.
- [5] **Evans CJ, Fowkes FGR, Ruckley CV, Lee AJ:** Prevalence of varicose veins and chronic venous insufficiency in men and women in the general population: Edinburgh Vein Study. *J Epidemiol Community Health* 1999, 53, 149–153.
- [6] **Andersson E, Hansson C, Swanbeck G:** Leg and foot ulcer prevalence and investigation of the peripheral arterial and venous circulation in a randomised elderly population. An epidemiological survey and clinical investigation. *Acta Derm Venereol* 1993, 73, 57–61.
- [7] **Raines JK, Almeida JJ:** Role of Physiologic Testing in Venous Disorders in: Bergan JJ *The Vein Book*, Academic Press, Waltham 2006, 47, 1<sup>st</sup> ed.
- [8] **Kistner RL, Eklöf B:** Classification and etiology of chronic venous disease. In: Gloviczki P, editor. *Handbook of venous disorders: guide-lines of the American Venous Forum*. Hodder Arnold, London 2009, 37–46, 3<sup>rd</sup> ed.
- [9] **Phillips MN, Dijkstra ML, Khin NY, Lane RJ:** Endovenous valve transfer for chronic deep venous insufficiency. *Eur J Vasc Endovasc Surg* 2013, 46, 360–365.
- [10] **Menyhei G, Gyevnar Z, Arato E, Kelemen O, Kollar L:** Conventional stripping versus cryostripping: a prospective randomised trial to compare improvement in quality of life and complications. *Eur J Vasc Endovasc Surg* 2008, 35, 218–223.
- [11] **Luebke T, Brunkwall J:** Meta-analysis of transilluminated powered phlebectomy for superficial varicosities. *J Cardiovasc Surg (Torino)* 2008, 49, 757–764.
- [12] **Lurie F, Creton D, Eklöf B:** Prospective randomized study of endovenous radiofrequency obliteration (closure procedure) vs ligation and stripping in a selected patient population (EVOLVES Study). *J Vasc Surg* 2003, 38, 207–214.
- [13] **Jones L, Braithwaite BD, Selwyn D, Cooke S, Earnshaw JJ:** Neovascularisation is the principal cause of varicose vein recurrence: results of a randomized trial of stripping the long saphenous vein. *Eur J Vasc Endovasc Surg* 1996, 12, 442–445.
- [14] **Perrin MR1, Guex JJ, Ruckley CV:** Recurrent varices after surgery (REVAS), a consensus document. REVAS group. *Cardiovasc Surg* 2000, 8, 233–245.
- [15] **Darke SG:** The morphology of recurrent varicose veins. *Eur J Vasc Surg* 1992, 6, 512–517.
- [16] **De Maeseneer MG, Ongena, KP, Van den Brande F, Van Schil PE, De Hert SG:** Duplex ultrasound assessment of neovascularization after sapheno-femoral sapheno-popliteal junction ligation. *Phlebology* 1997, 12, 64–68.
- [17] **Egan B, Donnelly M, Bresnihan M, Tierney S, Feeley M:** Neovascularization: an “innocent bystander” in recurrent varicose veins. *J Vasc Surg* 2006, 44, 1279–1284, discussion 1284.
- [18] **Geier B, Olbrich S, Barbera L, Stucker M, Mumme A:** Validity of the macroscopic identification of neovascularization at the saphenofemoral junction by the operating surgeon. *J Vasc Surg* 2005, 41, 64–68.
- [19] **van Rij AM, Jones GT, Hill BG, Amer M, Thomson IA, Pettigrew RA:** Mechanical inhibition of angiogenesis at the saphenofemoral junction in the surgical treatment of varicose veins: early results of a blinded randomized controlled trial. *Circulation* 2008, 118, 66–74.
- [20] **Allegra C, Antignani PL, Carlizza A:** Recurrent varicose veins following surgical treatment: our experience with five years follow-up. *Eur J Vasc Endovasc Surg* 2007, 33, 751–756.
- [21] **Kianifard B, Holdstock JM, Whiteley MS:** Radiofrequency ablation (VNUS closure) does not cause neo-vascularisation at the groin at one year: results of a case controlled study. *Surgeon* 2006, 4, 71–74.
- [22] **Politowski M, Szpak E, Marszałek Z:** Treatment of Varicose Veins of the Lower Extremities with the aid of Electrocoagulation. *Pol Przegl Chir* 1964, 36, 7–14.
- [23] **Goldman MP:** Closure of the greater saphenous vein with endoluminal radiofrequency thermal heating of the vein wall in combination with ambulatory phlebectomy: preliminary 6-month follow-up. *Dermatol Surg* 2000, 26, 452–456.
- [24] **Proebstle T:** Three-year European follow-up of endovenous radiofrequency-powered segmental thermal ablation of the great saphenous vein with or without treatment of calf varicosities. *J Vasc Interv Radiol* 2009, 20, 752–759.
- [25] **Almeida JJ, Kaufman J, Göckeritz O:** Radiofrequency Endovenous ClosureFast Versus Laser Ablation for the Treatment of Great Saphenous Reflux: A Multicenter, Single-Blinded, Randomized Study (RECOVERY Study). *J Vasc Interv Radiol* 2009, 20, 752–759.

- [26] Navarro L, Min RJ, Bone C: Endovenous laser: a new minimally invasive method of treatment for varicose veins: preliminary observations using an 810 nm diode laser. *Dermatol Surg* 2001, 27, 117–122.
- [27] The care of patients with varicose veins and associated chronic venous diseases: clinical practice guidelines of the Society for Vascular Surgery and the American Venous Forum. Gloviczki P, Comerota AJ, Dalsing MC, Eklof BG, Gillespie DL, et al, Wakefield TW; Society for Vascular Surgery; American Venous Forum. *J Vasc Surg* 2011, 53 (Suppl 5), 2S–48S.
- [28] van den Bos RR, Kockaert MA, Neumann HAM, Nijsten T: Technical Review of Endovenous Laser Therapy for Varicose Veins *Eur J Vasc Endovasc Surg* 2008, 35, 88–95.
- [29] Rasmussen LH, Lawaetz M, Bjoern L, Vennits B, Blemings A, Eklof B: Randomized clinical trial comparing endovenous laser ablation, radiofrequency ablation, foam sclerotherapy and surgical stripping for great saphenous varicose vein. *Br J Surg* 2011, 98, 1079–1087.
- [30] Luebke T, Brunkwall J: Systematic review and meta-analysis of endovenous radiofrequency obliteration, endovenous laser therapy and foam sclerotherapy for primary varicose veins. *J Cardiovasc Surg* 2008, 49, 213–223.
- [31] van den Bos RR, Milleret R, Neumann M, Nijsten T: Proof-of-principle study of steam ablation as novel thermal therapy for saphenous varicose veins. *J Vasc Surg* 2010, 53, 181–186.
- [32] Parsi K, Exner T, Connor DE, Herbert A, Ma DDF: The Lytic Effects of Detergent Sclerosants on Erythrocytes, Platelets, Endothelial Cells and Microparticles are Attenuated by Albumin and other Plasma Components *in Vitro Eur J Vasc Endovasc Surg* 2008, 36, 216–223.
- [33] Sarvananthan T, Shepherd AC, Willenberg T, Davies AH: Neurological complications of sclerotherapy for varicose veins. *J Vasc Surg* 2012, 55, 243–251.
- [34] Elias S, Raines J: Mechanochemical tumescentless endovenous ablation: final results of the initial clinical trial. *Phlebology* 2012, 27, 67–72.
- [35] Wang YM, Cheng LF, Li N: Histopathological study of vascular changes after intra-arterial and intravenous injection of N- butyl-2-cyanoacrylate. *Chin J Dig Dis* 2006, 7, 175–179.
- [36] Padberg FT Jr, Pappas PJ, Araki CT, Back TL, Hobson RW: Hemodynamic and clinical improvement after superficial vein ablation in primary combined venous insufficiency with ulceration. *J Vasc Surg* 1996, 24, 711–718.
- [37] Michaels JA, Campbell WB, Brazier JE: Randomised clinical trial, observational study and assessment of cost-effectiveness of the treatment of varicose veins (REACTIV trial). *Health Technol Assess* 2006, 13, 1–196, iii–iv.
- [38] Kanwar A, Hansrani M, Lees T, Stansby G: Trends in varicose vein therapy in England. *Ann R Coll Surg Engl* 2010, 92, 341–346.
- [39] Van Den Bos R, Arends L, Kockaert M, Neumann M, Nijsten T: Endovenous therapies of lower extremity varicosities: a meta-analysis. *J Vasc Surg* 2009, 49, 230–239.

### Address for correspondence:

Maciej Chwała  
Clinical Department of Vascular Surgery  
University Hospital  
Botaniczna 3  
31-503 Kraków  
Poland  
E-mail: mchwała@interia.pl

Conflict of interest: None declared

Received: 27.06.2013

Revised: 23.01.2014

Accepted: 15.10.2014